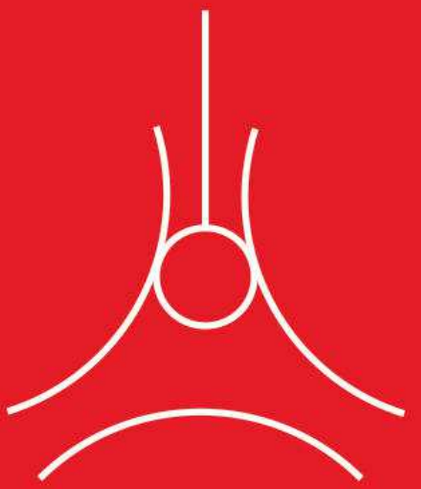

FETAL ENDOSCOPIC TRACHEAL OCCLUSION

KNOWING WHAT TO LOOK FOR MAY NOT BE EASY. KNOWING WHERE TO LOOK FOR HELP IS.

Texas Children's Fetal Center™ is home to one of the nation's largest congenital diaphragmatic hernia (CDH) programs, with outcomes among the best in the country.

Ranging from moderate to severe cases of CDH, we offer fetal endoscopic tracheal occlusion (FETO), a breakthrough research protocol with potential to dramatically improve lung growth prior to birth. Coupled with outstanding multidisciplinary, postnatal surgical care, this treatment gives more babies with CDH a chance at a healthy life. As one of the first in the country to offer FETO, with one of the most experienced staffs in North America, we're proud to be on the leading edge of this revolutionary care.

Send us your toughest cases. We're known for delivering.

Learn more: **women.texaschildrens.org/fetal** or **1-877-FetalRx**

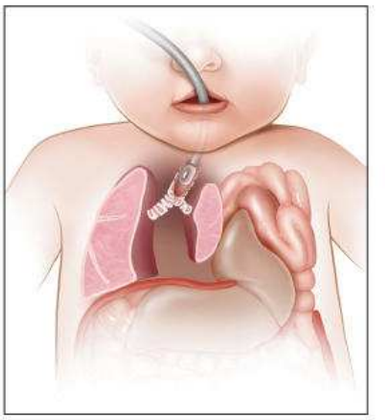

FETO is a minimally invasive procedure in which a tiny balloon is inserted into the fetus to plug the trachea. The balloon is inflated, left in place for several weeks to allow the fetus' lungs to grow, then removed a few weeks prior to delivery.

Texas Children's Hospital®

Pavilion for Women

Predictors of Malignancy in Hyperechoic Breast Lesions

Lara Nassar, MD, FRCR, Ghada Issa, MD, Zeina Farah, MPH, Youssef El Zein, MD, Ghina Berjawi, MD, FRCR

Objectives—Hyperechogenicity has been strongly associated with benign breast lesions. Although it is correct in most cases, hyperechogenicity must not always be considered synonymous with benignancy, as hyperechoic breast cancers do occur. The purpose of this study was to review clinical and imaging characteristics of hyperechoic breast lesions, looking for features associated with malignancy.

Methods—Institutional Review Board approval was granted for this research. A total of 19,417 sonographic examinations were performed between January 2009 and June 2013. Among these, hyperechoic lesions with histologic diagnoses, stability on long-term follow-up, or characteristic imaging appearances were included in the study. The patients' clinical charts, mammograms, and sonograms were reviewed. The clinical and imaging features were recorded, and the data was analyzed by the χ^2 test, Fisher exact test, and independent-samples *t* test, looking for statistically significant predictors of malignancy.

Results—Among the 19,417 scans, 42 patients (0.2%) with 44 hyperechoic lesions were identified. Twenty-six lesions fulfilling the inclusion criteria were included in the study: 5 malignancies (3 invasive ductal carcinomas, 1 invasive lobular carcinoma, and 1 invasive mucinous cancer) and 21 benign lesions. An irregular shape, a nonparallel orientation, and noncircumscribed margins were significantly associated with the risk of malignancy (P = .002, .02, and .01, respectively).

Conclusions—A hyperechoic breast lesion must not always be assumed to be benign. Instead, a full sonographic assessment according to the American College of Radiology Breast Imaging Reporting and Data System descriptors is needed for correct characterization and avoidance of misdiagnosis.

Key Words—breast; breast ultrasound; hyperechoic; malignancy; sonography

From the days when sonography was solely used to differentiate solid from cystic lesions and when all solid lesions were subjected to tissue diagnosis, our understanding of breast masses has substantially evolved. With the use of the American College of Radiology Breast Imaging Reporting and Data System (BI-RADS) descriptors, breast radiologists are now able to predict with a high degree of confidence the benign or malignant nature of breast lesions, hence decreasing the rate of missed cancers as well as unnecessary biopsies.

One subgroup of breast lesions, hyperechoic masses, has been traditionally thought of as almost synonymous with benignity. Recent studies, however, are increasingly stressing on the fact that although very rare, breast cancers may occasionally be hyperechoic.[1–5]

Received May 7, 2015, from the Department of Diagnostic Radiology, American University of Beirut Medical Center, Beirut, Lebanon (L.N., G.I., Y.E.Z., G.B.); and Epidemiological Surveillance Program, Ministry of Public Health, Beirut, Lebanon (Z.F.). Revision requested May 28, 2015. Revised manuscript accepted for publication July 28, 2015.

We thank Tatiana Khoury, MD, and Nadim El Majzoub, MD, fort their help in the preparation of the manuscript.

Address correspondence to Ghina Berjawi, MD, FRCR, Department of Diagnostic Radiology, American University of Beirut Medical Center, PO Box: 11-0236, Riad El Solh, Beirut 1107 2020, Lebanon.

E-mail: gb02@aub.edu.lb

Abbreviations

BI-RADS, Breast Imaging Reporting and Data System

doi:10.7863/ultra.15.05020

As such, a more thorough understanding of this category of breast lesions is needed to avoid misdiagnosis. To our knowledge, the sonographic features of hyperechoic breast cancers have only rarely been studied.[6,7] An irregular shape, a nonparallel orientation, noncircumscribed margins, and the presence of a hypoechoic area within the lesion show a statistically significant association with malignancy. This article intends to review the clinical characteristics and sonographic features of benign and malignant hyperechoic lesions encountered over 4 years to study the reproducibility of previously demonstrated correlations and evaluate other possible predictors of malignancy.

Materials and Methods

The Institutional Review Board at the American University of Beirut Medical Center granted approval for this retrospective study, and informed consent for publication of the manuscript and the figures was waived. No identifiable information was used in the manuscript or on the figures.

A picture archiving and communication system search was conducted for reports of breast sonographic examinations performed between January 2009 and June 2013, looking for those mentioning "hyperechoic" or "echogenic" breast lesions. During this period, sonographic examinations were performed with a 5–13-MHz linear transducer and an Acuson Antares ultrasound system (Siemens Medical Solutions, Mountain View, CA). In concordance with the BI-RADS lexicon, hyperechogenicity was defined in our study as echogenicity greater than that of the subcutaneous fat.[8] The presence of hypoechoic components larger than 5 mm within hyperechoic lesions has prompted some authors to classify them as having mixed echogenicity rather than as hyperechoic lesions[3]; however, as there is no general consensus in this regard, and to maintain comparability with previous studies, lesions with a maximum of 30% hypoechoic components were included in the study and considered to have heterogeneous internal echogenicity, in contradistinction to those showing homogeneous hyperechogenicity (Figure 1).

Lesions that had histologic diagnoses (obtained from ultrasound-guided 14-gauge core biopsies) or those determined to be benign based on follow-up imaging over at least 2 years or that had pathognomonic imaging appearances (mammography revealing a typical oil cyst with rim calcifications and a pathognomonic hyperechoic appearance with a snowstorm pattern of a silicone granuloma) were included in the study. When mammograms were available, they would usually be reviewed by the radiologist before performing the sonographic examination. The available mammograms were also retrospectively reviewed by the authors.

Figure 1. Homogeneous (**A**) and heterogeneous (**B**) hyperechoic breast lesions (arrows). **A**, Transverse sonogram obtained during screening of a woman with breast implants. Biopsy of the hyperechoic mass showed fat necrosis. **B**, Transverse sonogram of a palpable lesion in a young woman. Biopsy showed sclerosing adenosis.

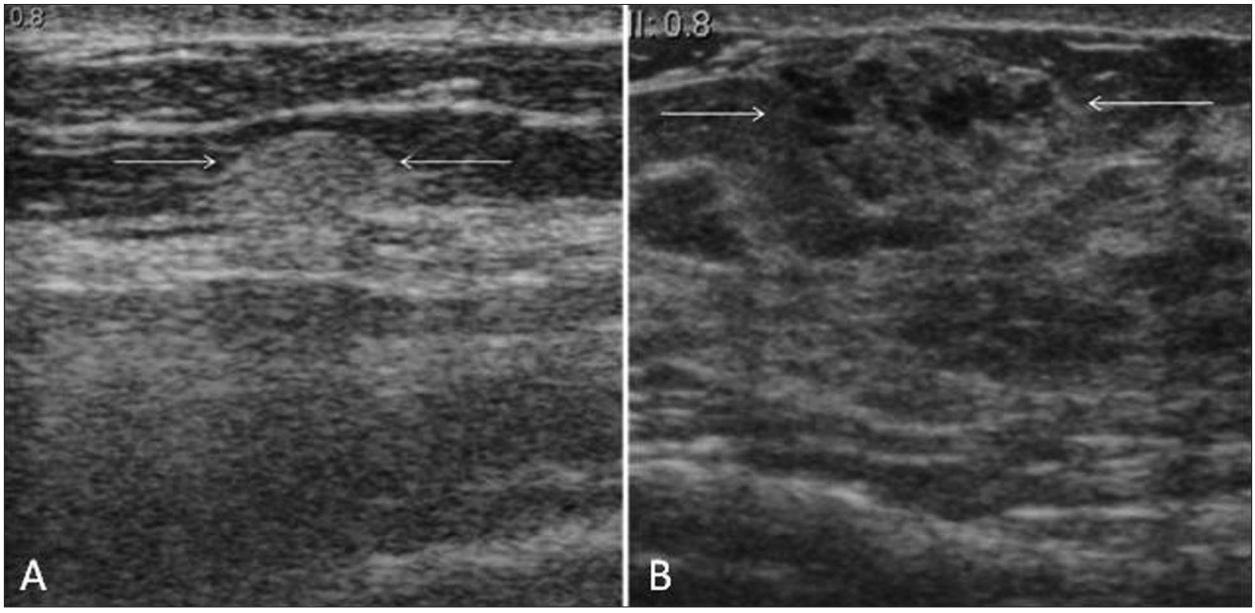

The following imaging features were retrospectively reviewed: size, margins, shape, orientation, posterior acoustic features, internal echo texture, presence of a corresponding mammographic abnormality, and its nature when present. The patients' charts were reviewed; the age of the patient, indication for sonography, presence of a palpable lesion, and presence of a personal or family history of breast cancer were noted.

Statistical analyses using the χ^2 test, Fisher exact test and independent-samples *t* test were performed, looking for any significant correlation between the studied clinical and sonographic features and a diagnosis of malignancy. A *P* value of less than .05 was considered statistically significant.

Results

A total of 19,417 whole-breast sonographic examinations were performed during the studied period. Forty-four hyperechoic lesions in 42 patients (0.2% of patients) were identified (1 patient with 3 lesions and 41 patients with 1 lesion each). The sonograms of 7 patients were not available for review, and 11 patients were lost to follow-up. Thus, the study sample consisted of 26 lesions in 25 patients (24 women and 1 man) between 23 and 72 years of age (mean, 46.2 years). The lesions ranged in size between 4 and 35 mm (mean, 15.08 mm).

Twenty of the studied lesions underwent ultrasound-guided core biopsy. At the final histologic analyses, there were 15 benign lesions (fibroadenoma [n = 2], fat necrosis [n = 2], sclerosing adenosis [n = 2], benign breast tissue [n = 2], intracystic papilloma [n = 1], fibrocystic changes [n = 1], angiolipoma [n = 1], lipoma [n = 1], focal fibrosis [n = 1], myofibroblastoma [n = 1], and pilomatricoma [n = 1]) and 5 malignant lesions (invasive ductal carcinoma [n = 3], invasive lobular carcinoma [n = 1], and invasive mucinous cancer [n = 1]).

Three lesions were diagnosed as benign by stable size on follow-up (2 probable lipomas in 1 patient and 1 hamartoma in 1 patient, which were stable for 2 and 7 years respectively). Three hyperechoic lesions had typical benign imaging characteristics and were classified as BI-RADS category 2, so a biopsy was not performed (2 silicone granulomas showing the typical hyperechogenicity with the snowstorm pattern and 1 oil cyst with characteristic rim calcifications; Figure 2).

The clinical features of the study sample are described in Table 1. Sonographic examinations were performed for screening purposes in 10 cases and for diagnostic purposes in 15. Mammograms were available for 21 cases, 9 of which showed corresponding abnormalities (masses [2 invasive ductal carcinomas, 1 invasive mucinous carcinoma, 1 fibroadenoma, 1 myofibroblastoma, 1 silicone granuloma, and 1 hamartoma], focal asymmetry with architectural distortion [invasive ductal carcinoma], and rim calcifications [oil cyst]). Mammographic findings were negative in 12 cases. Five of these had suspected palpable masses on physical examination (2 cases of benign breast tissue, 1 focal fibrosis, 1 pilomatricoma, and 1 probable lipoma). The remaining 7 lesions, including 1 malignancy (invasive lobular carcinoma), showed no suspicious features on physical examination and as such were considered purely sonographic (Figure 3). The malignancy was not palpable

Figure 2. Images from a patient with a history of left mastectomy and right breast reduction. **A**, Screening sonogram showing a circumscribed homogeneous hyperechoic nodule (arrows) with a nonparallel orientation. **B**, Craniocaudal mammographic view showing a fatty lesion with typical rim calcifications, consistent with an oil cyst. The lesion was classified as BI-RADS category 2. **C**, Sonogram obtained 2 years later showing liquefaction, now with a cystic appearance of the lesion, confirming its benign nature.

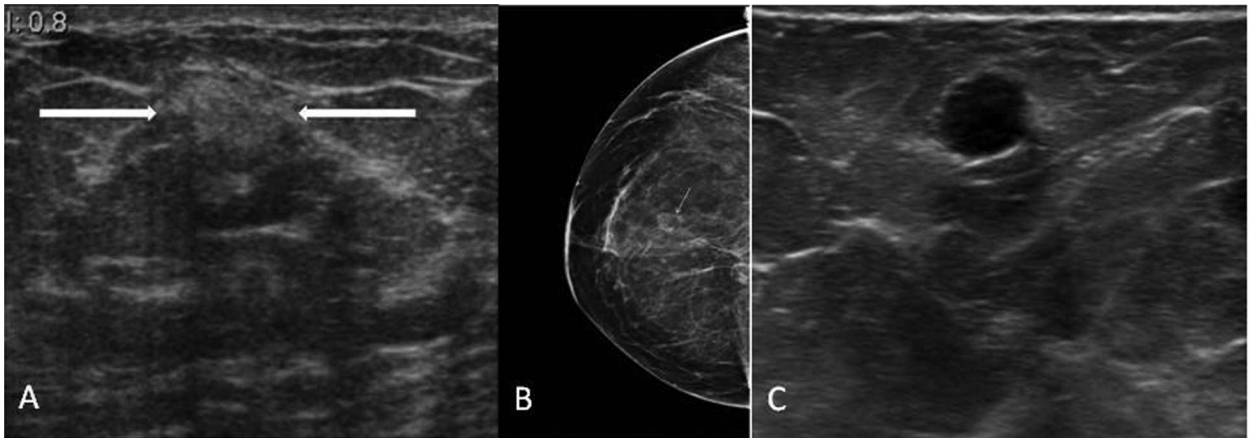

and showed a heterogeneous internal echo texture and noncircumscribed borders. Although this malignancy itself was not evident on the mammogram, it was suspected because of the presence of axillary adenopathies.

Most of the examined patients reported no personal or family history of breast cancer (15 patients). A personal history of breast cancer was present in 4 cases and 2 women had a positive family history of breast cancer, 1 in her daughter and the other in her sister. Data were not available for the rest of the examined patients.

Table 1. Clinical Characteristics of the Study Sample

Characteristic	Malignant	Benign	*P*
Age, y	52.60 ± 12.30	44.67 ± 14.81	.280
Palpable lesion			>.999
Absent	2 (50.0)	9 (50.0)	
Present	2 (50.0)	9 (50.0)	
Personal history			.530
Absent	4 (100)	11 (73.3)	
Present	0 (0)	4 (26.7)	
Family history			>.999
Absent	4 (100)	11 (84.6)	
Present	0 (0)	2 (15.4)	
Indication			>.999
Screening	2 (40.0)	8 (45.0)	
Palpable nodule	2 (40.0)	9 (40.0)	
Suspected lesion on mammography	1 (20.0)	2 (10.0)	
Evaluation of MRI-detected lesion	0 (0)	1 (5.0)	

Data are presented as mean ± SD and number (percent). Data were not available for all patients. MRI indicates magnetic resonance imaging.

The imaging characteristics of the studied lesions are described in Table 2. There was a statistically significant difference in the sonographic appearances of benign and malignant lesions; an irregular shape, a nonparallel orientation, and noncircumscribed margins were significant predictors of malignancy. Although malignant lesions were more likely to show a heterogeneous internal echo texture than benign lesions and more likely to show a corresponding mammographic abnormality, these factors did not reach statistical significance. The size of the lesion, posterior sound transmission, presence of a palpable lesion, and presence of a personal or a family history of breast cancer did not correlate with an increased risk of malignancy.

Discussion

Hyperechogenicity is a rare feature reported on breast sonography, especially in cancerous lesions.[6,9] In fact, hyperechogenicity has been described as one of the most reliable predictors of benignity,[10] with its negative predictive value for cancer reported as 100%.[11] Several studies have shown similar findings. In their series of 403 lesions, Hong et al[12] found only 6 hyperechoic masses, none of which were malignant. Similarly, no cancer was found among 10 hyperechoic masses in a series of 256 masses by Del Frate et al.[9] Although very rare, hyperechoic cancers do, however, occur and may account for 0.4% to 2% of all breast cancers. The increased echogenicity may be seen as a thick peripheral halo surrounding a hypoechoic center (Figure 3).[2,6,7]

Figure 3. BI-RADS category 5 palpable left breast mass. Mammography also showed enlarged right axillary adenopathy but no suspicious right breast lesion. **A**, Sonogram showing a heterogeneous hyperechoic lesion with noncircumscribed margins and a parallel orientation. **B**, Cropped lateral view of the right breast after biopsy. The dense dot within the red circle represents the clip marker deployed within the lesion after biopsy. The lesion was not apparent on mammography. Biopsy showed invasive lobular carcinoma.

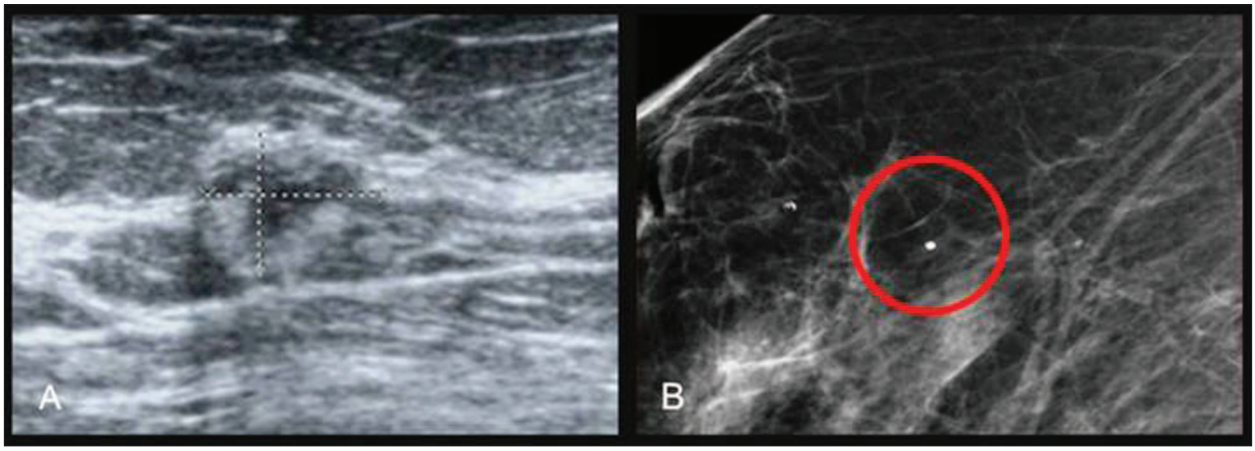

A hyperechoic appearance of breast cancer is thought to be related to an increase in the acoustic interfaces due to the heterogeneity of the tumor in contrast to the homogeneous breast, leading to an increase in the reflected echoes.[4] This appearance can be seen mainly in invasive lobular cancer because of its typical infiltrative growth pattern, which has been described as rows of single cells in the surrounding parenchyma and as concentric rings around normal ducts.[13] This feature is also seen in other histologic types with tumor cellular heterogeneity, such as cribriform, tubular, solid-nest, and scirrhous patterns.[14]

A hyperechoic appearance of cancer carries no specific implications with regard to the prognosis.[3] Although invasive lobular cancer has been previously described as being 10 times more likely to be hyperechoic than invasive ductal carcinoma,[15] only 1 invasive lobular cancer was diagnosed among the 5 malignancies in our study.

In complex cystic lesions of the breast, hyperechogenicity is a significant predictor of malignancy.[16] Only 2 of our lesions appeared as echogenic intracystic masses; these turned out to be an intraductal papilloma and fibrocystic changes with apocrine metaplasia. No malignancy in our series appeared as a complex cystic lesion (Figure 4).

Table 2. Imaging Characteristics of the 26 Hyperechoic Lesions

Characteristic	Malignant	Benign	*P*
Size, mm	22.80 ± 11.90	13.24 ± 6.69	.149
Shape			.002
Oval	1 (20.0)	18 (85.7)	
Irregular	4 (80.0)	1 (4.8)	
Round	0 (0)	2 (9.5)	
Orientation			.020
Parallel	1 (20.0)	17 (81.0)	
Nonparallel	4 (80.0)	4 (19.0)	
Margins			.010
Circumscribed	1 (20.0)	18 (85.7)	
Noncircumscribed	4 (80.0)	3 (14.3)	
Internal echo texture			.628
Homogeneous	1 (20.0)	8 (38.1)	
Heterogeneous	4 (80.0)	13 (61.9)	
Posterior sound transmission			>.999
None	4 (80.0)	14 (66.7)	
Shadowing	1 (20.0)	6 (28.6)	
Enhancement	0 (0)	1 (4.8)	
Correlative lesion on mammography			.119
Absent	1 (20.0)	11 (68.8)	
Present	4 (80.0)	5 (31.3)	

Data are presented as mean ± SD and number percent. Mammograms were available for 21 cases.

Figure 4. Transverse sonogram (**A**) and Doppler scan (**B**) showing an intracystic vascular hyperechoic mass, which was found by biopsy to represent fibrocystic changes with apocrine metaplasia.

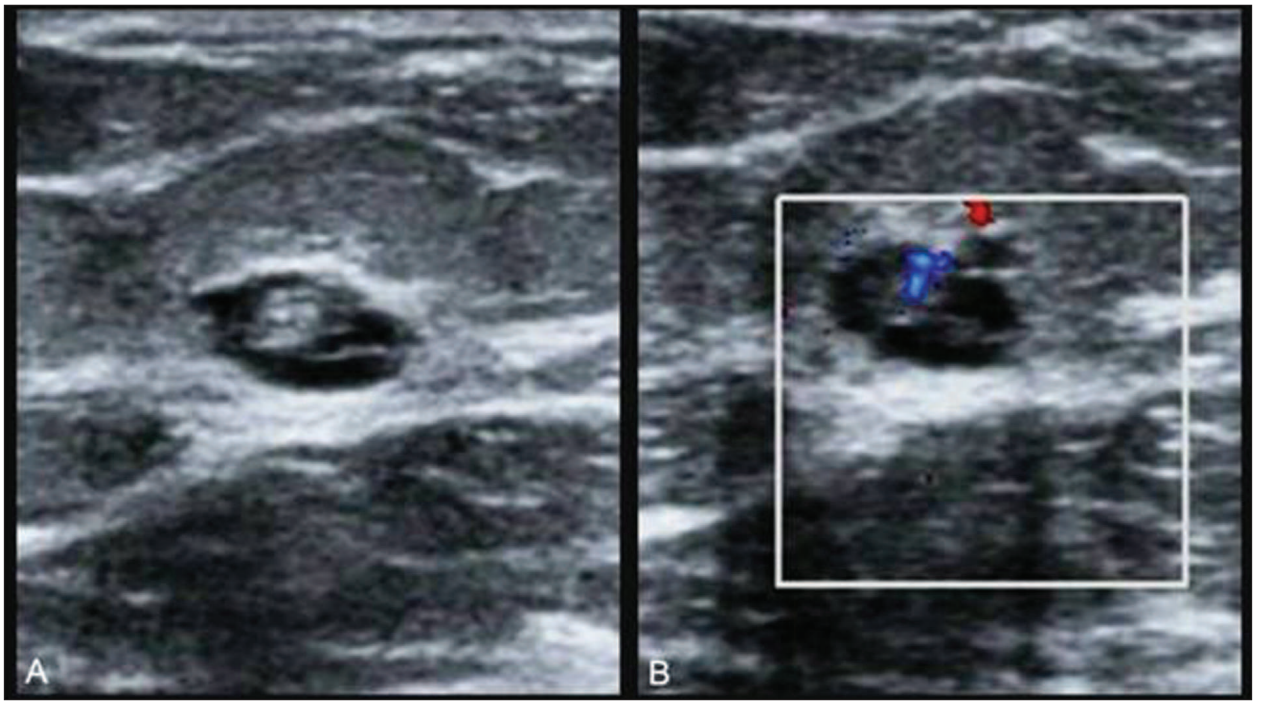

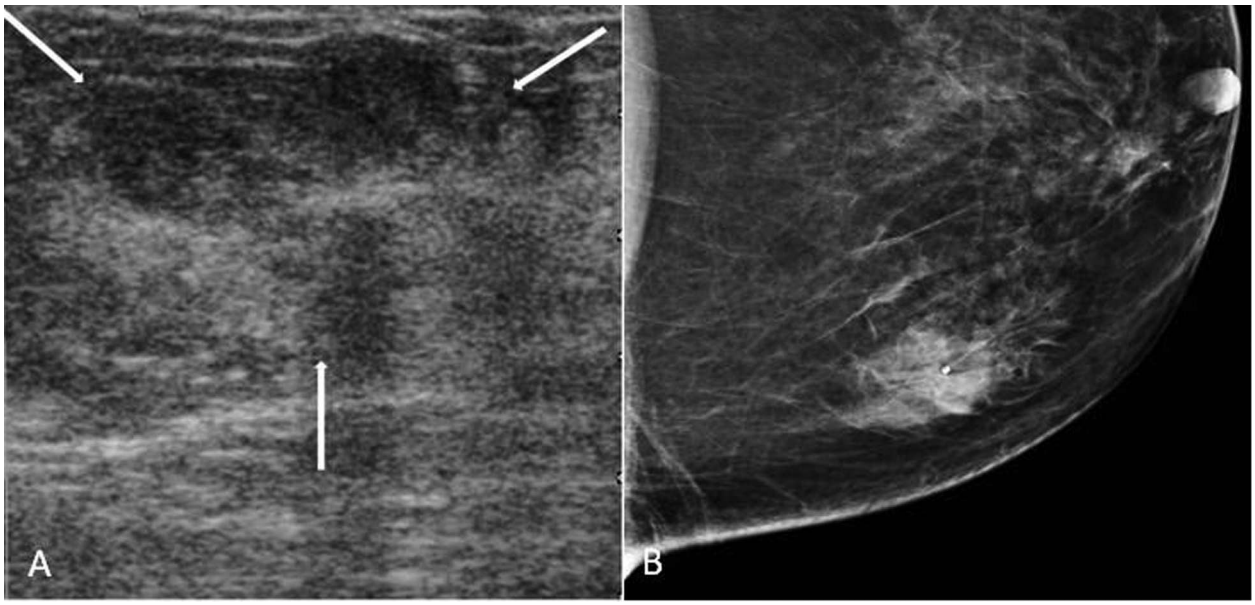

Figure 5. **A**, Transverse sonogram obtained for assessment of a suspicious mass (arrows) seen on mammography (**B**), appearing as an irregular heterogeneous noncircumscribed hyperechoic mass. The central shadowing seen on the sonogram is related to the postbiopsy clip marker deployed within the mass. Biopsy showed invasive mucinous cancer.

One of our malignant hyperechoic masses was a mucinous carcinoma. The sonographic appearance of mucinous cancer may vary depending on whether the tumor is a pure or mixed carcinoma.[17] However, lesions are usually typically either isoechoic or hypoechoic.[17,18] Hyperechoic mucinous cancers have only rarely been described (Figure 5).[6,7]

It is important to keep in mind other types of breast malignancies, which we did not encounter in our study but that could also appear as hyperechoic breast lesions. These include lymphoma, angiosarcoma, liposarcoma, and metastases to the breast. Lymphomas account for about 0.15% of malignant breast lesions,[19] with secondary breast lymphomas being more common than primary disease.[20] They appear predominantly hypoechoic,[21] occasionally almost pseudocystic, but may also be shown as hyperechoic masses in up to 23% of cases.[22] Lymphoma in the breasts lacks spiculations, architectural distortion, and calcifications, therefore allowing differentiation from primary breast carcinoma.[21] Angiosarcoma is rare; it may present as either a primary malignancy in younger women or may be secondary to lymphedema or irradiation.[23] In their review of 26 mammary angiosarcomas, Yang et al[24] found that 62% of these lesions appeared as focal masses. Of these, 54% were hyperechoic or of mixed echogenicity. Liposarcoma is also a rare primary sarcoma of the breast that is most aggressive when affecting young pregnant or lactating women.[25] This tumor usually appears as a complex echogenic mass.[4] Metastases to the breast, typically from melanoma, may also appear hyperechoic.[5,26]

As previously demonstrated by Linda et al[6] and Nam et al[7] we found that noncircumscribed margins, an irregular shape, and a nonparallel orientation occurred significantly more frequently in malignant lesions. Although a heterogeneous internal echo texture occurred relatively more frequently in malignant lesions, which were also more likely to show corresponding mammographic abnormalities, this characteristic did not reach statistical significance. Stavros et al[11] noted that the 100% negative predictive value of hyperechogenicity can be only reached if strictly applying the condition of a homogeneously hyperechoic lesion; we did, however, encounter a case of invasive ductal cancer with a homogeneously hyperechoic pattern (Figure 6).

What is remarkable, however, is that the 3 statistically significant features that correlated with malignancy among the studied hyperechoic masses (irregular shape, nonparallel orientation, and noncircumscribed margins) are well-demonstrated risk factors for malignancy among hypoechoic breast lesions. This finding implies that regardless of the echogenicity of the mass, sonographic assessment should be the same, and evaluation of all of the BI-RADS descriptors is important to correctly categorize the lesions.

Figure 6. Coned-down mediolateral oblique view of the right breast and longitudinal sonogram obtained for assessment of a palpable mass. **A**, Mammogram showing an irregular mass with architectural distortion. **B**, Sonogram showing an irregular noncircumscribed but homogeneous hyperechoic mass (arrows). Biopsy showed high-grade invasive ductal cancer.

We recognize the limitations of our study. First, it was a retrospective evaluation of previously acquired static images collected by a search of patient reports, whereby very benign-looking hyperechoic lesions might have not been reported, hence increasing the rate of malignancies in our study. Second, our patient sample was small, which was directly related to the fact that hyperechoic lesions of the breast are rare and limits the power of the conclusions drawn from this study. Moreover, in the absence of a clear definition of a hyperechoic lesion and to maintain comparability with previous studies, we included lesions that were heterogeneous but predominantly hyperechoic. We realize that this factor might have affected our results.

In conclusion, hyperechoic lesions of the breast are not always benign; an irregular shape, noncircumscribed margins, and a nonparallel orientation are significant predictors of malignancy in predominantly hyperechoic lesions. A full sonographic assessment according to the BI-RADS descriptors must be performed to correctly characterize and avoid misdiagnosis of rare hyperechoic breast cancer.

References

1. Linda A, Zuiani C, Lorenzon M, et al. The wide spectrum of hyperechoic lesions of the breast. *Clin Radiol* 2011; 66:559–565.
2. Skaane P, Engedal K. Analysis of sonographic features in the differentiation of fibroadenoma and invasive ductal carcinoma. *AJR Am J Roentgenol* 1998; 170:109–114.
3. Soon PS, Vallentine J, Palmer A, Magarey CJ, Schwartz P, Morris DL. Echogenicity of breast cancer: is it of prognostic value? *Breast* 2004; 13:194–199.
4. Adrada B, Wu Y, Yang W. Hyperechoic lesions of the breast: radiologic-histopathologic correlation. *AJR Am J Roentgenol* 2013; 200:W518–W530.
5. Gao Y, Slanetz PJ, Eisenberg RL. Echogenic breast masses at US: to biopsy or not to biopsy? *Radiographics* 2013; 33:419–434.
6. Linda A, Zuiani C, Lorenzon M, et al. Hyperechoic lesions of the breast: not always benign. *AJR Am J Roentgenol* 2011; 196:1219–1224.
7. Nam SY, Ko ES, Han BK, Shin S, Ko EY, Shin JH, Hahn SY. Ultrasonographic hyperechoic lesions of the breast: are they always benign? *Acta Radiol* 2015; 56:18–24.

8. Mendelson EB, Böhm-Vélez M, Berg WA, et al. ACR BI-RADS® ultrasound. In: *ACR BI-RADS® Atlas, Breast Imaging Reporting and Data System*. Reston, VA, American College of Radiology; 2013:149.
9. Del Frate C, Bestagno A, Cerniato R, et al. Sonographic criteria for differentiation of benign and malignant solid breast lesions: size is of value. *Radiol Med* 2006; 111:783–796.
10. Rahbar G, Sie AC, Hansen GC, et al. Benign versus malignant solid breast masses: US differentiation. *Radiology* 1999; 213:889–894.
11. Stavros AT, Thickman D, Rapp CL, Dennis MA, Parker SH, Sisney GA. Solid breast nodules: use of sonography to distinguish between benign and malignant lesions. *Radiology* 1995; 196:123–134.
12. Hong AS, Rosen EL, Soo MS, Baker JA. BI-RADS for sonography: positive and negative predictive values of sonographic features. *AJR Am J Roentgenol* 2005; 184:1260–1265.
13. Whitman GJ, Huynh PT, Patel P, Wilson J, Cantu A, Krishnamurthy S. Sonography of invasive lobular carcinoma. *Ultrasound Clin* 2006; 1:645–660.
14. Kobayashi T, Shinozaki H, Yomon M, et al. Hyperechoic pattern in breast cancer: its bio-acoustical genesis and tissue characterization. *J UOEH* 1989; 11:181–187.
15. Cawson JN, Law EM, Kavanagh AM. Invasive lobular carcinoma: sonographic features of cancers detected in a breast screen program. *Australas Radiol* 2001; 45:25–30.
16. Tea MK, Grimm C, Heinz-Peer G, Delancey J, Singer C. The predictive value of suspicious sonographic characteristics in atypical cyst-like breast lesions. *Breast* 2011; 20:165–169.
17. Memis A, Ozdemir N, Parildar M, Ustun EE, Erhan Y. Mucinous (colloid) breast cancer: mammographic and US features with histologic correlation. *Eur J Radiol* 2000; 35:39–43.
18. Liu H, Tan H, Cheng Y, Zhang X, Gu Y, Peng W. Imaging findings in mucinous breast carcinoma and correlating factors. *Eur J Radiol* 2011; 80:706–712.
19. Giardini R, Piccolo C, Rilke F. Primary non-Hodgkin's lymphomas of the female breast. *Cancer* 1992; 69:725–735.
20. Surov A, Holzhausen HJ, Wienke A, et al. Primary and secondary breast lymphoma: prevalence, clinical signs and radiological features. *Br J Radiol* 2012; 85:e195–e205.
21. Lyou CY, Yang SK, Choe DH, Lee BH, Kim KH. Mammographic and sonographic findings of primary breast lymphoma. *Clin Imaging* 2007; 31:234–238.
22. Yang WT, Lane DL, Le-Petross HT, Abruzzo LV, Macapinlac HA. Breast lymphoma: imaging findings of 32 tumors in 27 patients. *Radiology* 2007; 245:692–702.
23. Glazebrook KN, Magut MJ, Reynolds C. Angiosarcoma of the breast. *AJR Am J Roentgenol* 2008; 190:533–538.
24. Yang WT, Hennessy BT, Dryden MJ, Valero V, Hunt KK, Krishnamurthy S. Mammary angiosarcomas: imaging findings in 24 patients. *Radiology* 2007; 242:725–734.
25. Nandipati KC, Nerkar H, Satterfield J, Velagapudi M, Ruder U, Sung KJ. Pleomorphic liposarcoma of the breast mimicking breast abscess in a 19-year-old postpartum female: a case report and review of the literature. *Breast J* 2010; 16:537–540.
26. Catalano O, Voit C, Sandomenico F, et al. Previously reported sonographic appearances of regional melanoma metastases are not likely due to necrosis. *J Ultrasound Med* 2011; 30:1041–1049.